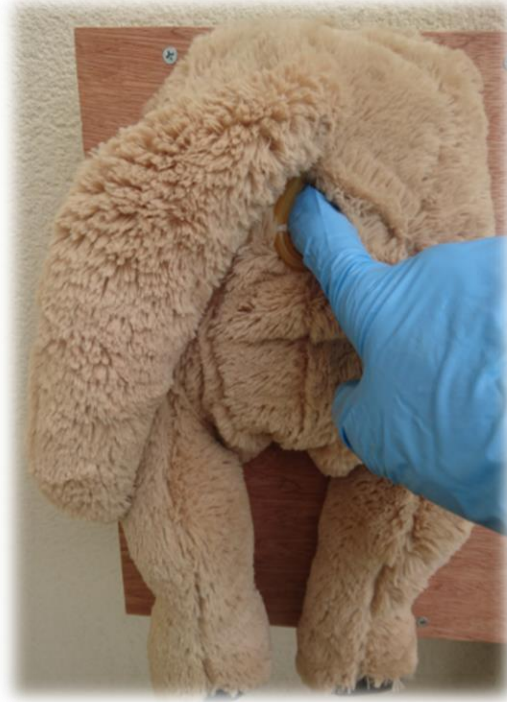

Canine Prostate Examination



Disclaimer

A series of booklets has been developed by the Clinical Skills Lab team (staff, recent graduates and students) from the School of Veterinary Sciences, University of Bristol, UK.

Please note:

- Each booklet illustrates one way to perform a skill and it is acknowledged that there are often other approaches. Before using the booklets students should check with their university or college whether the approach illustrated is acceptable in their context or whether an alternative method should be used.
- The booklets are made available in good faith and may be subject to changes.
- In using these booklets you must adopt safe working procedures and take your own risk assessments, checked by your university, college etc. The University of Bristol will not be liable for any loss or damage resulting from failure to adhere to such practices.

This work is under the Creative Commons Attribution-NonCommercial-NoDerivatives 4.0 International License.



© The University of Bristol, 2019



Equipment for this station:

- Canine prostate model (3 Ikea dogs mounted on a wooden board)
- The models represent 3 entire male Labrador-size dogs with different prostatic conditions:
 - Normal
 - Hyperplasia (both lobes enlarged)
 - Tumour (enlarged lobe with uneven surface)
- Non-sterile vinyl hand gloves

Considerations for this station:

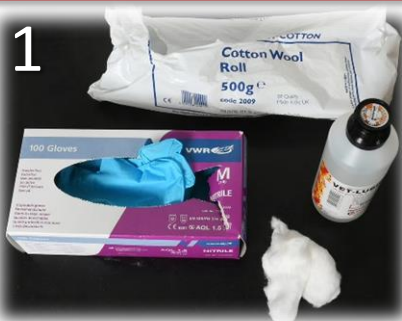- With a real dog ensure it is adequately and safely restrained e.g. ask an assistant to help
- If the dog is aggressive or in pain a muzzle should be applied (see 'CSL_D02 Fitting a Muzzle')
- The examination should be undertaken with the dog in a standing position
- The models represent entire male dogs; neutered males typically have a smaller prostate

Anyone working in the Clinical Skills Lab must read the 'CSL_I01 Induction' and agree to abide by the 'CSL_I00 House Rules' & 'CSL_I02 Lab Area Rules'

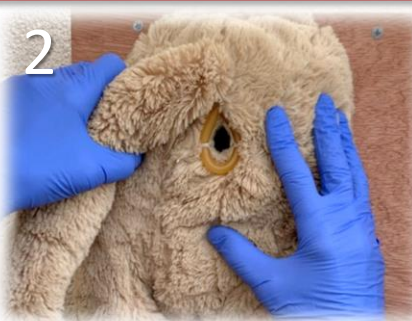Please inform a member of staff if equipment is damaged or about to run out.

Clinical Skills:

Canine Prostate Examination



Prepare all equipment:
For the model - vinyl gloves.
With a real animal – vinyl gloves, lubricant and cotton wool; an assistant to restrain the dog in the standing position; a muzzle.
Put on the gloves.



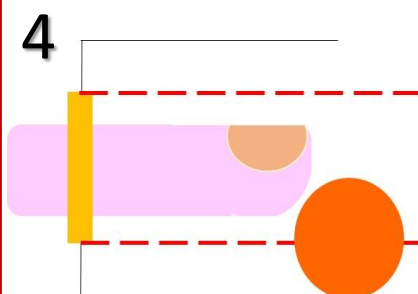
Hold the tail near the base with your non-dominant hand & lift it up or to the side. Check dog's perineal area, testes and scrotum for any abnormalities.
In the real animal, tell the assistant and owner that you are about to start the internal examination. Place lubricant on your index finger and the anal sphincter. N.B. Do not use lubricant with the model.



Insert the index finger through the anal sphincter using a slight twisting action (with finger tip pad facing down/ventral).

In the real animal, check the anal glands for any abnormalities.

N.B. The dog model in the middle of the wooden board has a palpable anal gland on the left side (see next page).

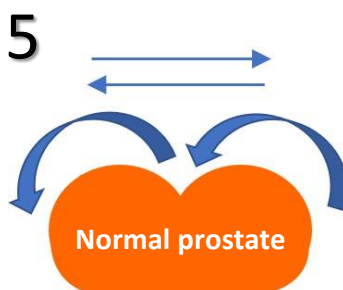


Advance your index finger along the ventral floor.

In the real animal, gently sweep from side to side to check the rectal wall for abnormalities.

N.B. There is no rectal wall represented in the model.

Once your finger is fully inserted the caudal aspect of the prostate gland should be palpable.



Examine the prostate:

Sweep your finger from the right side over first lobe into sulcus then over left lobe. Repeat the movement from left to right. Attempt to feel the cranial border of the gland (this may not be possible in larger dogs).

Normal prostate is bi-lobed, smooth & firm; 3-5 cm wide, 1.5-2.5 cm caudo-cranial.



Examine each model (**before turning to the next page**):

Assess the size, symmetry, shape & firmness by carefully examining and comparing each lobe. Also feel for irregularities on the surface.

In the real animal, note if the dog feels pain at any point.

Once the examination is complete, withdraw the finger slowly.



Clinical Skills:

Canine Prostate Examination

Examine each of the three models




NORMAL

Examination findings:

The lobes are equal size, have a smooth surface and are firm.

In an entire male dog, each lobe is typically about 2-3 cm wide, 2-3 cm high, 1.5-2.5 cm caudo-cranial, although the size varies depending on breed and age. If a dog is neutered the size of the prostate will be smaller.



HYPERPLASIA


Examination findings: Both lobes are enlarged and are usually approximately equal size, with a smooth surface & firm consistency.

ANAL GLAND

This model has a palpable **left** anal gland. Anal glands are located at 4 & 8 o'clock (8 on the model) **just inside** the anal sphincter.

With your index finger just inside the anal sphincter move the tip to the left side and gently palpate the anal gland between your finger and thumb (on the outside).

*N.B. The gland in the model **cannot** be expressed.*



TUMOUR

Examination findings:

The lobe/s have an uneven surface, one or both may be enlarged, typically with small protrusions (firm bumps).

Other prostatic conditions:

In addition to the normal and pathological conditions represented by the models other conditions include prostatic cysts and prostatic abscesses.

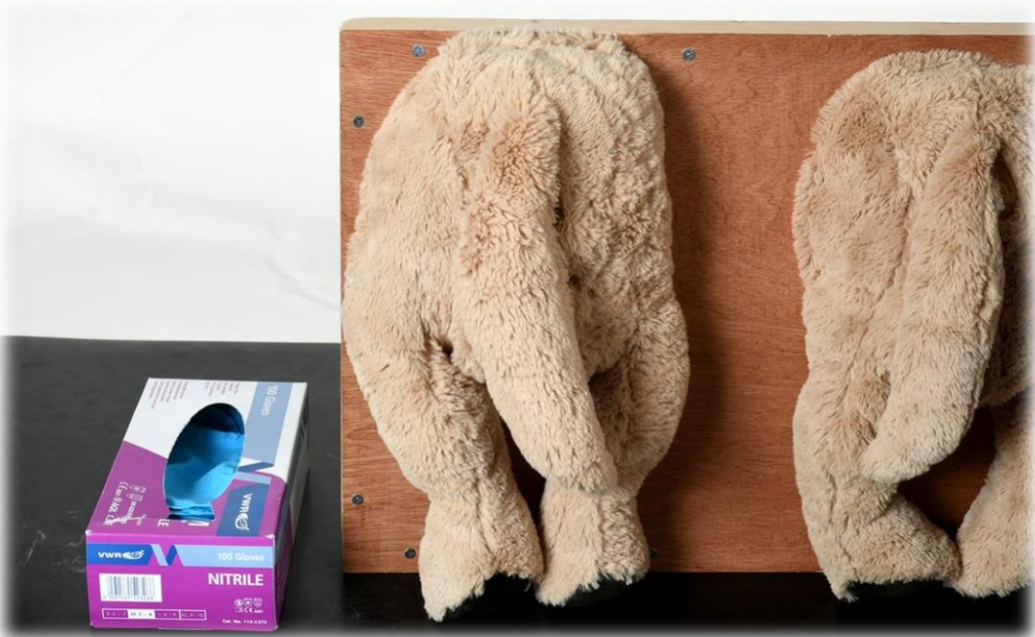

University of
BRISTOL

Resetting the station: Canine Prostate Examination

1. Dispose of gloves in a bin

Station ready for the next person:



Please inform a member of staff if equipment is damaged or about to run out.

I wish I'd known:

Canine Prostate Examination

- Remember to warn the owner and assistant at the point when you are about to start the internal examination as the dog may react.
- Restraint is important and helpful e.g. by an assistant, and if necessary (or in doubt) apply a muzzle.
- Remember to use lubrication on your finger and applied to the anal sphincter before inserting your finger.
- Always be gently and thorough; move your finger towards the prostate slowly and carefully; ensure the examination is comprehensive i.e. over the surface of each lobe, assess size (absolute and relative), feel for firmness/consistency/texture and any abnormalities.
- The prostate is smaller in castrated dogs compared to entire males; remember to check the scrotum and testes (if present).
- In larger dogs the prostate will be further in and it may only be possible to palpate the caudal aspect.
- As part of a complete examination also check the perineal area, anus, anal glands and rectum for any abnormalities.
- The anal glands are palpated (to L & R) just inside the anal sphincter. Tip: Do not insert your finger too far into the rectum i.e. as soon as your finger is through the anal sphincter turn the tip sideways & backwards to palpate the gland between your finger & thumb (on the outside).